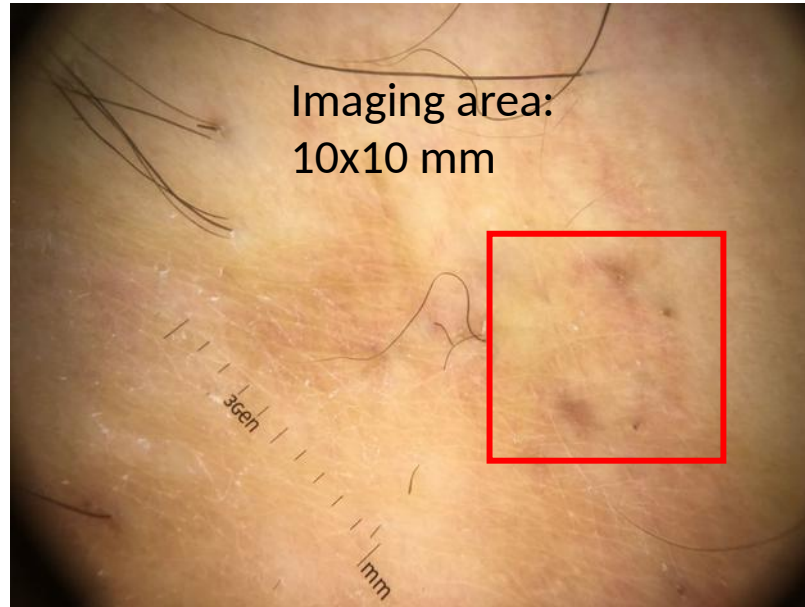
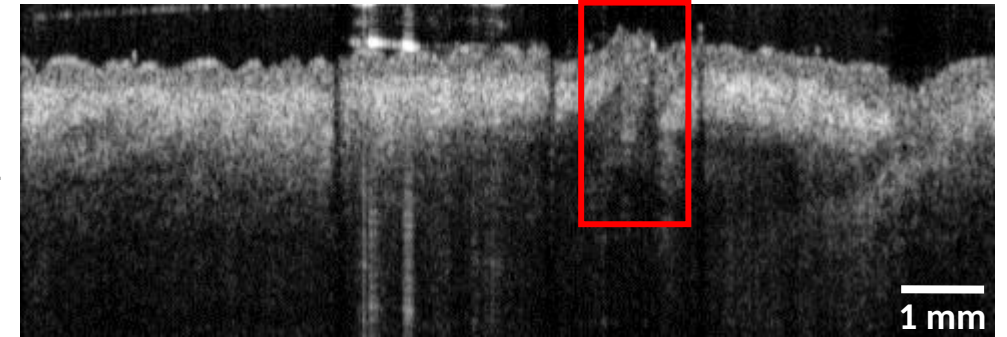


## Clinical image

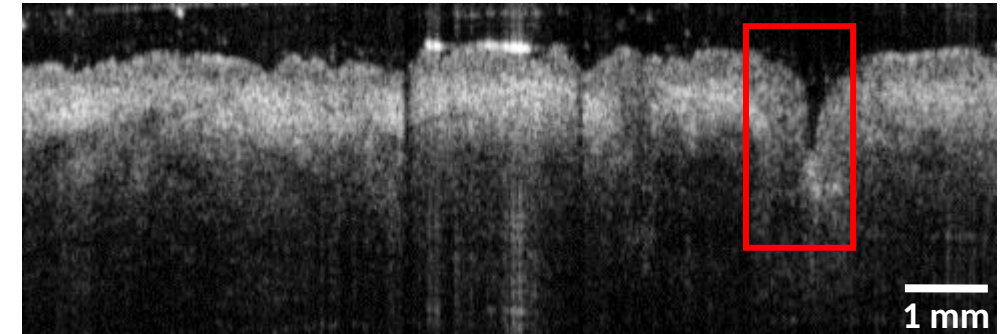


## Optical Coherence Tomography

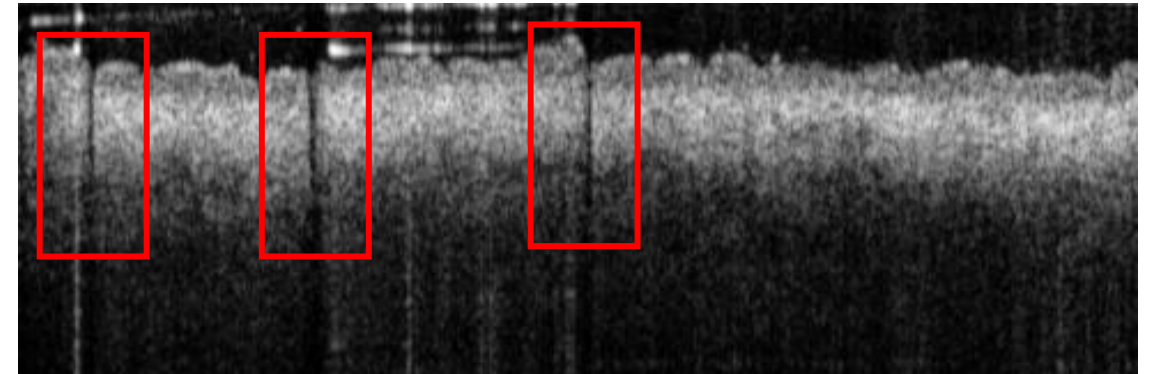
Position 1



Position 2




Cross-section of structure given by OCT,  
fly through of the whole volume (10x10  
mm)



Enface view of capillaries given by OCTA, 10x10mm

0-0.5 mm in depth



0.5-1 mm in depth

