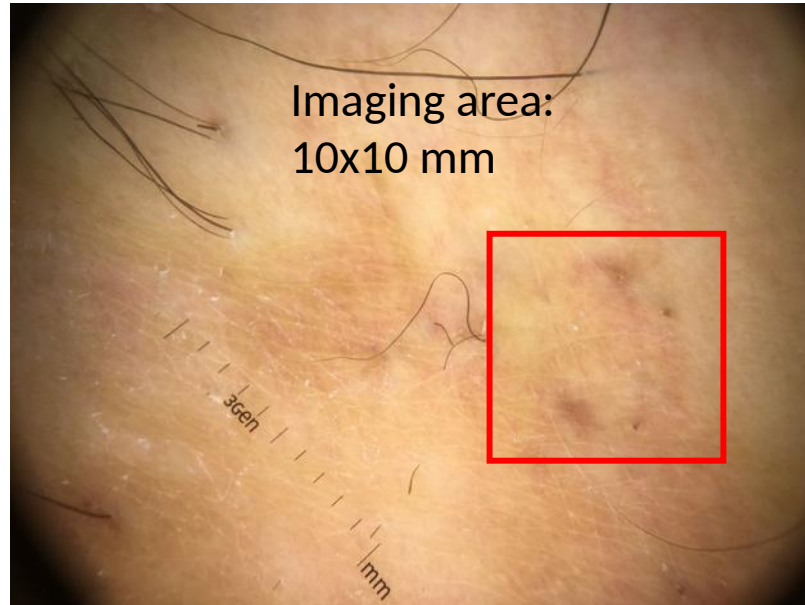
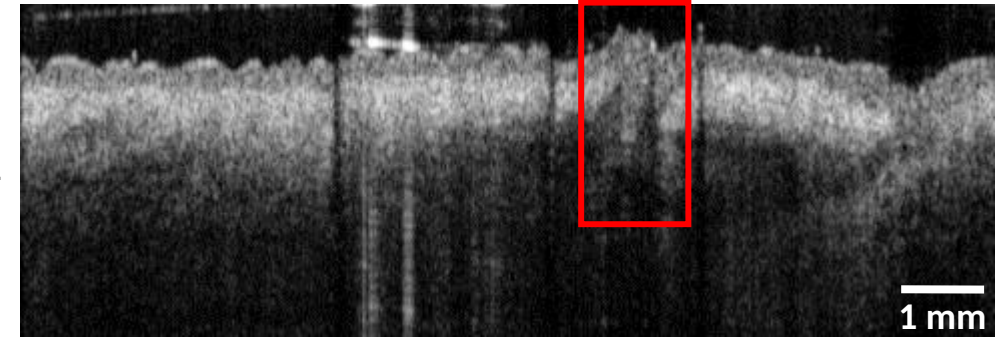


Clinical image

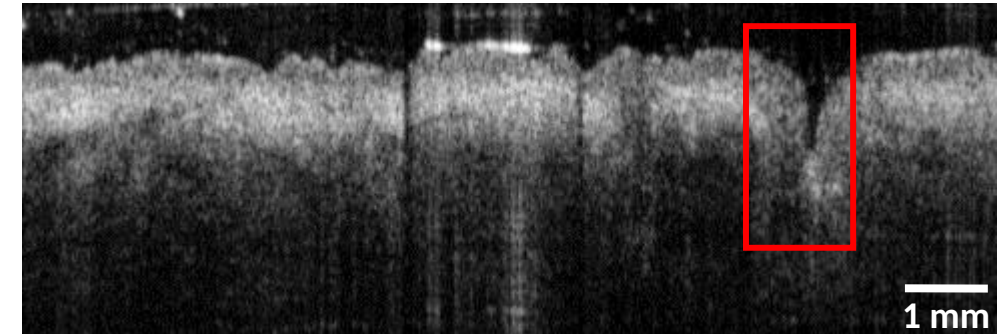


Optical Coherence Tomography

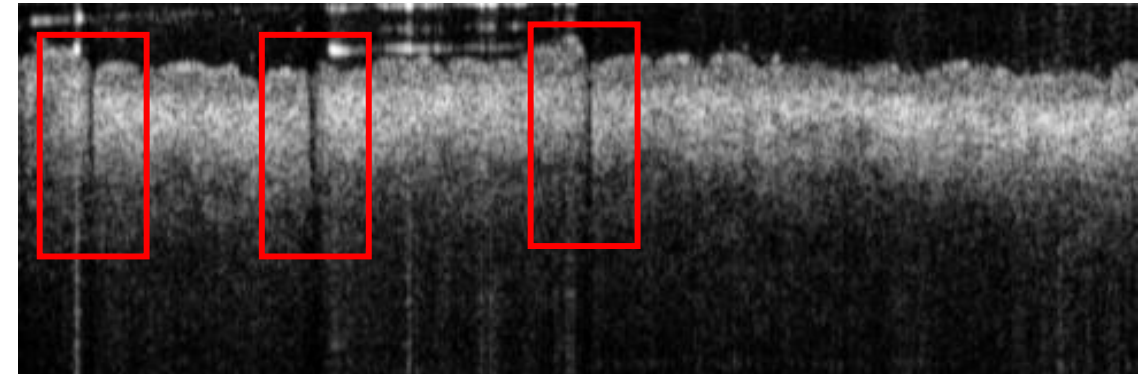
Position 1




Position 2



Cross-section of structure given by OCT,
fly through of the whole volume (10x10
mm)



0-0.5 mm in depth



0.5-1 mm in depth

